UNIVERSITY OF
EASTERN FINLAND

Quantitative MRI biomarkers of post-traumatic epilepsy and cognitive impairment after lateral fluid-percussion injury

Eppu Manninen, Kuopio bio-MRI workshop, June 1, 2022

Study design

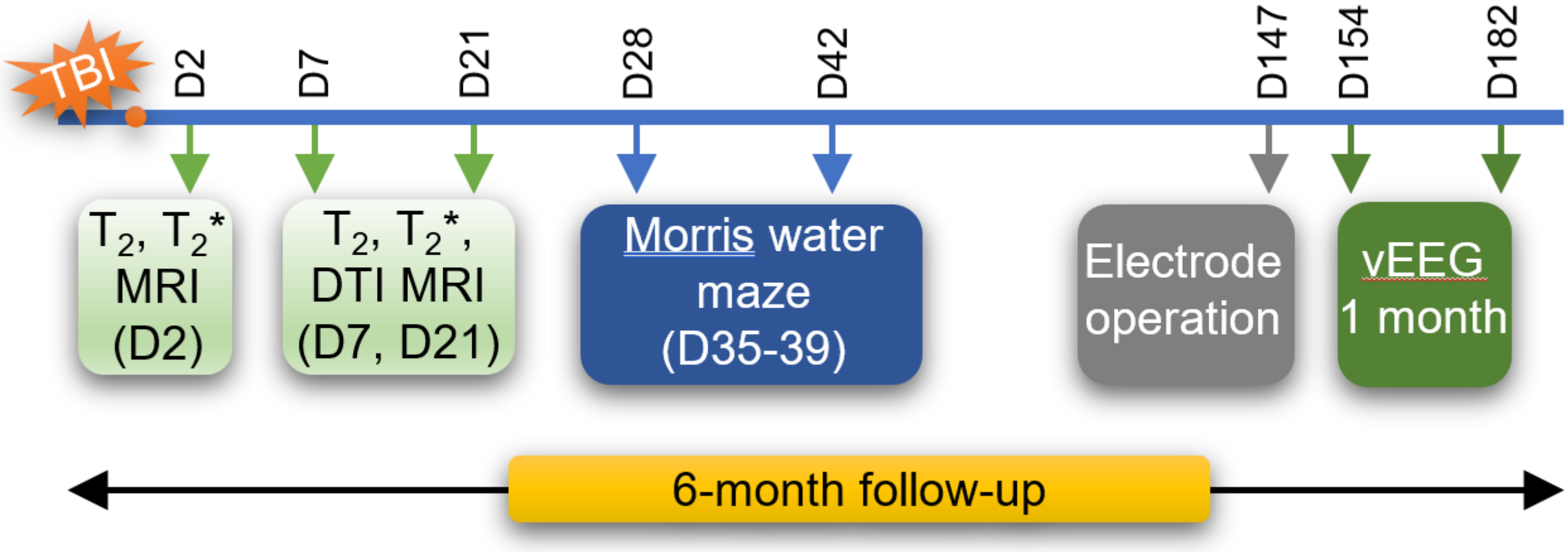

MRI analyses

- Hypothesis-driven analyses

1. Perilesional cortex
2. Thalamus
3. Hippocampus

DOI: 10.1089/neu.2019.6796

Perilesional cortex

- Early lesion severity and volume classification
  - Predicts necrotic lesion progression
  - Does not predict emergence of post-traumatic epilepsy

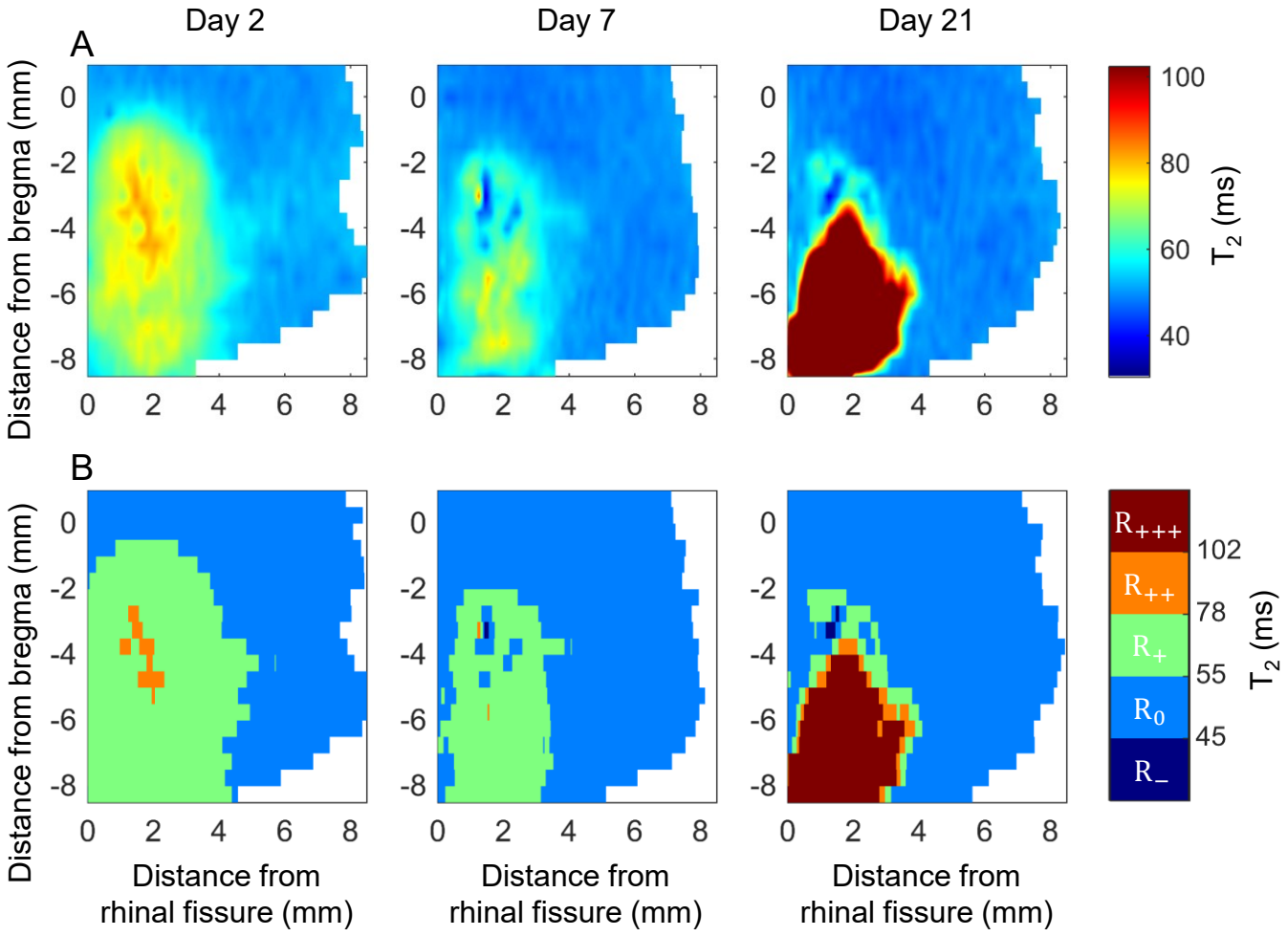

DOI: 10.1111/epi.16986

Thalamus

- Ventroposterior nucleus
- Mean and SD of T_2, T_2*, DTI parameters predict emergence of post-traumatic epilepsy

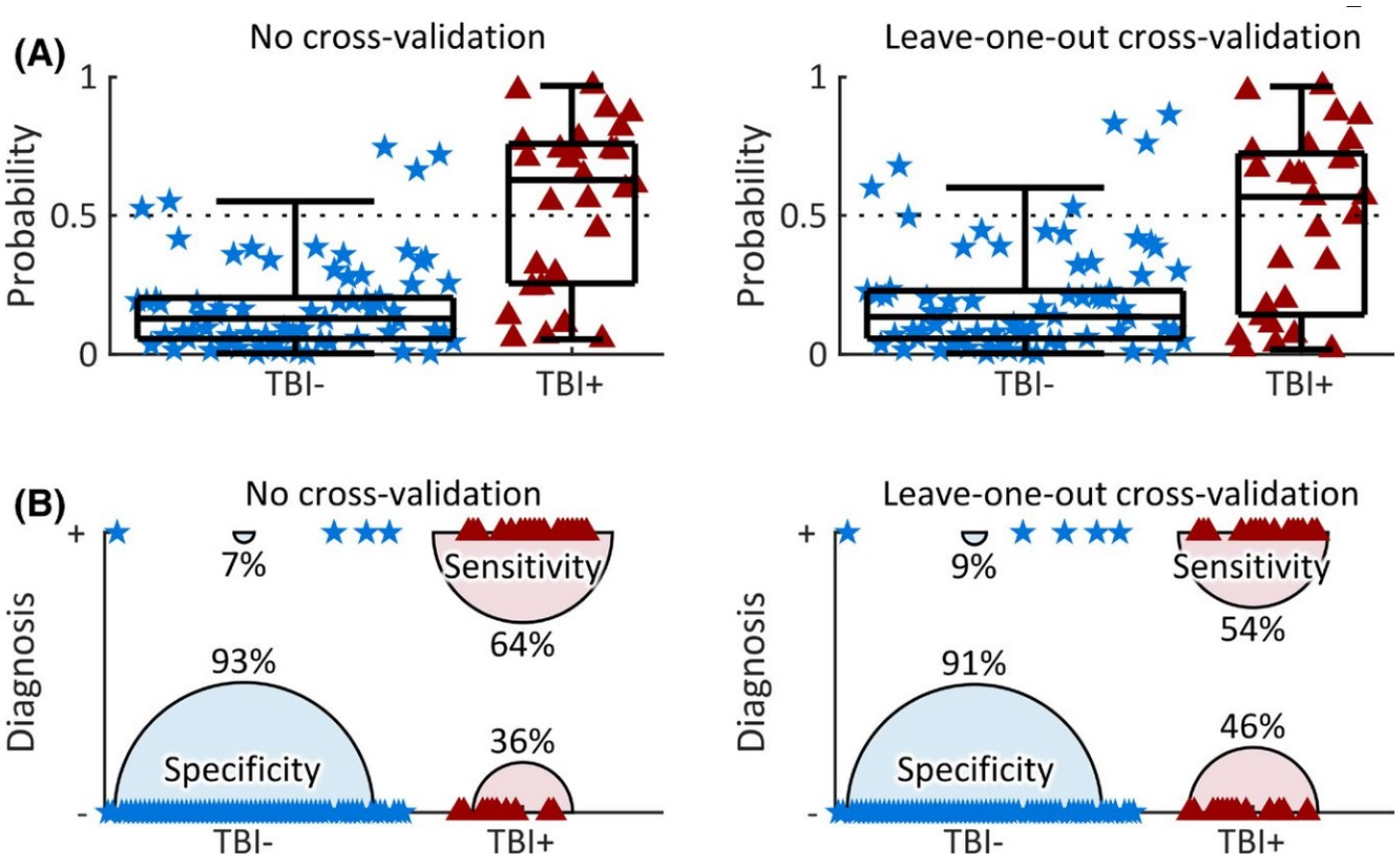

Hippocampus

- Analysis at points along septotemporal hippocampal axis
- T_2, T_2*, DTI parameters
  - Did not predict epilepsy
  - Predicted cognitive impairment

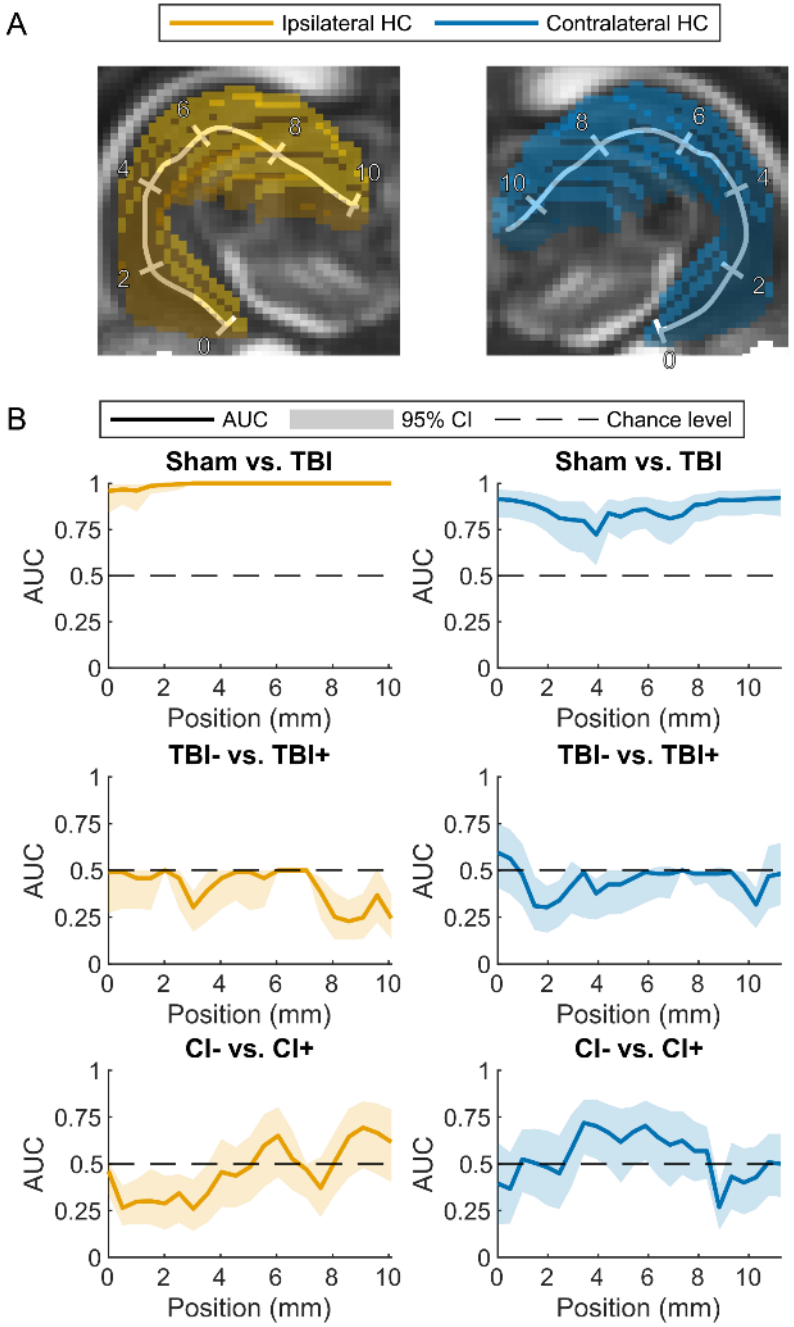

Acknowledgements

- UEF A.I. Virtanen Institute research groups
  - Biomedical MRI (Olli Gröhn)
  - Epilepsy Research (Asla Pitkänen)
  - Biomedical Image Analysis (Jussi Tohka)
  - Multiscale imaging group (Alejandra Sierra Lopez)
- EPITARGET (EU 7th Framework Programme)
- Alfred Kordelin Foundation