A.I.VIRTANEN INSTITUTE

UNIVERSITY OF EASTERN FINLAND

A multiscale tissue assessment in a rat model of mild traumatic brain injury

Isabel San Martín, Michela Fratini, Gaetano Campi, Manfred Burghammer, Tilmann Grunewald, Raimo A. Salo, Omar Narvaez, Manisha Aggarwal, Jussi Tohka, and Alejandra Sierra

19th Kuopio bio-MRI workshop

Introduction

- Mild traumatic brain injury (mTBI) is the most common form of acquired brain injury caused by an external force into the brain (affects 200-700 out of 100000 people/year)
- Conventional magnetic resonance imaging (MRI) techniques limited to detect microstructural changes related to mTBI

➢ **Aim: To evaluate the potential and limitations of diffusion tensor imaging (DTI) to detect tissue microstructural changes after mTBI in combination with multiscale assessment by light microscopy and scanning micro-X-ray diffraction (SμXRD)**

Material and Methods

- **Lateral fluid percussion injury model** (0.97 ± 0.06 atm)
  - Adult male Sprague-Dawley rats (mTBI=3; sham-operated=2)
- **Ex vivo DTI**
  - 11.7 Bruker NMR spectrometer
  - 3D weighted gradient- and spin-echo (DW-GRASE) sequence
  - DTI maps
- **Histology**
  - Nissl and gold chloride stainings (cyto- and myeloarchitecture)
  - 2D Structure tensor-(ST) based (AI, anisotropy index) and automated cell counting (CD, cell density) analyses
- **SμXRD**
  - ID13 beamline of the European Synchrotron Radiation Facility
  - Myelin structure at the nanoscale level (λ_L, λ_H, lamellar and hexagonal period and C_L, C_H lamellar and hexagonal content)
- **Statistical analyses**
  - Multiple linear regression: $y_{kj} = \boldsymbol{b}^T \boldsymbol{x}_{kj} + c + e_{kj}$ parameter to be explained (y_{kj}), vector of explaining parameters ($\boldsymbol{x}_{kj}$), region (j) animal (k), regression parameters ($\boldsymbol{b}$ and c), normally distributed i.i.d. errors (e_{kj})

Results

Thirty-five days after mTBI

- Changes in DTI parameters (lower FA. CL, CP; higher RD and CS)
- Axonal damage (white arrows) and loss of myelinated axons (white asterisks) and gliosis (black arrows)
- ST-analyses revealed lower AI values, and automated cell counting showed higher CD values
- Different stages of myelin damage based on myelin content and period

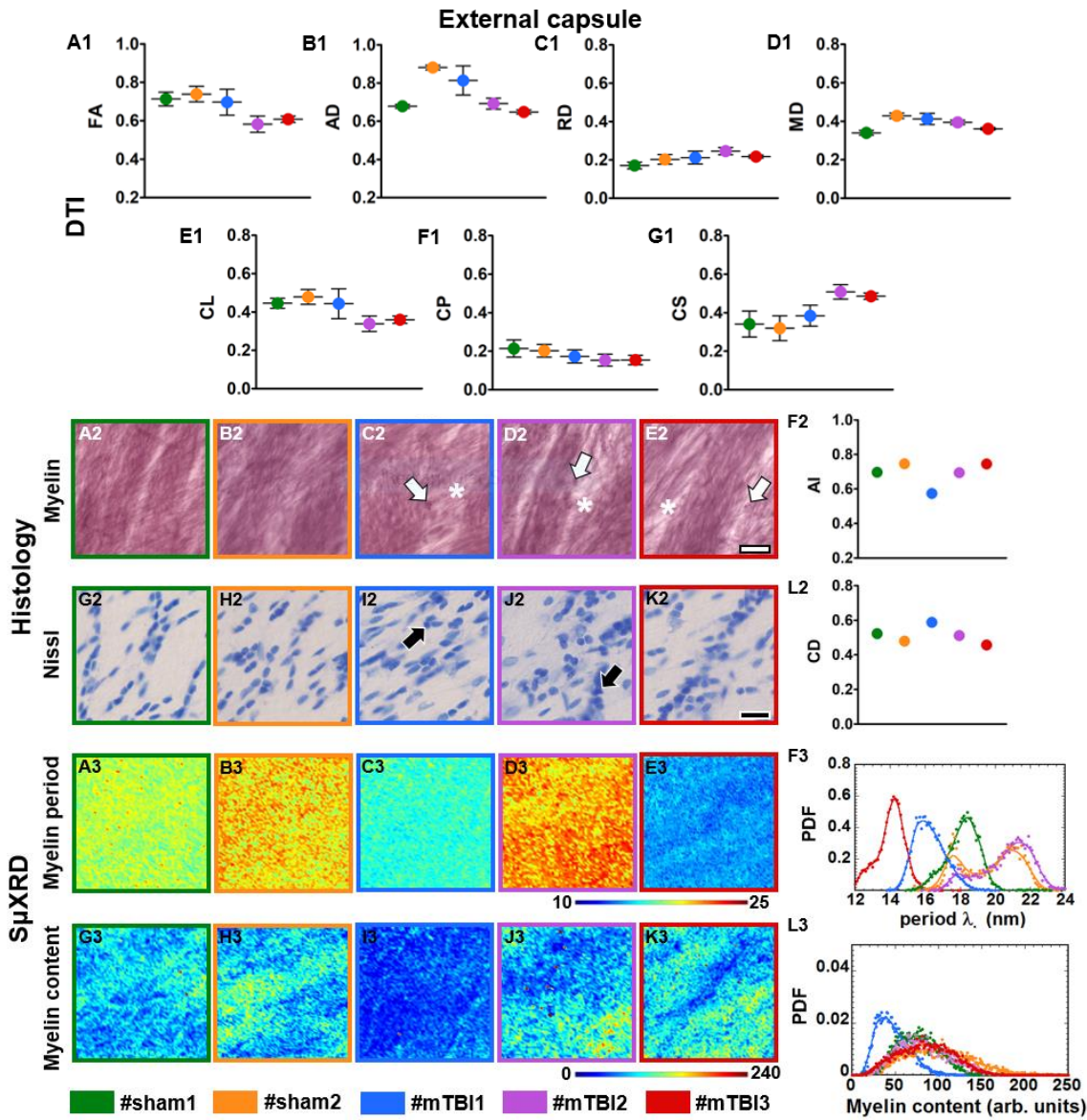

Results

- Moderate correlation between DTI and histology

	DTI	
	R^2 (95% CI)	R^2 adj
AI	**0.57** (0.10, 0.67)	0.45
CD	**0.30** (0.00, 0.44)	0.11

- Low correlation between SμXRD to DTI and histology

	DTI	
	R^2 (95% CI)	R^2 adj
C_L	**0.21** (0.00, 0.35)	0.01
λ_L	**0.04** (0.00, 0.07)	-0.21
C_H	**0.36** (0.00, 0.50)	0.19
λ_H	**0.07** (0.00, 0.12)	-0.17

	Histology	
	R^2 (95% CI)	R^2 adj
C_L	**0.23** (0.00, 0.44)	0.16
λ_L	**0.03** (0.00, 0.19)	-0.06
C_H	**0.29** (0.00, 0.49)	0.22
λ_H	**0.01** (0.00, 0.12)	-0.08

AI, anisotropy index; CD, cell density; C_H, hexagonal phase content; λ_H, hexagonal phase period; C_L, lamellar phase content; λ_L, lamellar phase period.

Conclusions

- On day 35 post-mTBI= DTI changes, axonal damage, reduced myelin density and gliosis in histology, and different stages of ultrastructural degeneration of myelin by SμXRD

- Potential of DTI to detect loss of myelinated axons and gliosis, and low detection of ongoing ultrastructural damage of myelin

➢ **This study opens new ways to examine mild tissue damage using multiple imaging modalities and their detection by non-invasive MRI methods**

Acknowledgments

Research Director Alejandra Sierra Lopez
Professor Jussi Tohka
PhD. Michela Fratini
PhD. Gaetano Campi
PhD. Manfred Burghammer
European Synchroton Radiation Facility (ESRF)
University of Eastern Finland
PhD. Tilmann Grunewald
Dr. Raimo Salo
MSc. Omar Narvaez
Dr. Ali Abdollahzadeh
Maarit Pulkkinen

Funding

SUOMALAINEN TIEDEAKATEMIA
FINNISH ACADEMY OF SCIENCE AND LETTERS
ACADEMIA SCIENTIARUM FENNICA

ACADEMY OF FINLAND